

Gold Marker Placement Worksheet: Cranial

Gold Markers for localization with the ACCULOC® IGRT and pReference® Stereotactic Radiosurgery Systems

Bone markers are pure gold spheres. They are placed during a simple 20-minute outpatient procedure under local anesthetic. Tools to facilitate marker placement include drill bits, guides and a tool for holding the marker during implantation.



Gold Marker Placement

Simple "puncture wound" technique for the placement of the gold markers is described here in summary form.

The following tools are needed:

- 2mm Surgical Drill Bit
- Surgical Drill - Cordless, Electric
- Drill Sleeve
- Marker Placement Tool
- Two sets of Gold Markers
- *Bone Wax (Horsley's Method)



*Bone wax is typically available from the hospital's surgical supplies.

The following steps for placing the Gold Markers are illustrated in Figures 1-4:

- Set drill depth - Fig. 1
- Make the puncture wound
- Place the drill sleeve - Fig. 2
- Drill a 3mm deep hole in the skull bone - Fig. 3
- Use bone wax to adhere a Gold Marker to the placement tool - Fig. 4
- Push the gold marker down the sleeve into the hole in the skull - Fig. 4
- Recommended locations for Gold Markers - Fig. 5
- Remove sleeve and close wound

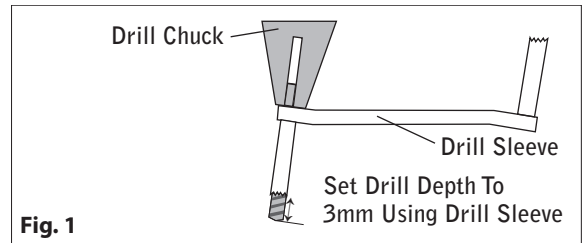


Fig. 1

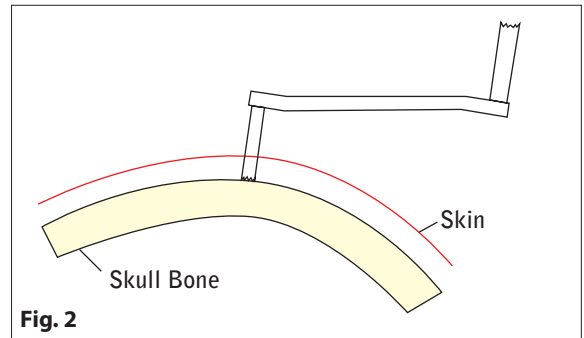


Fig. 2

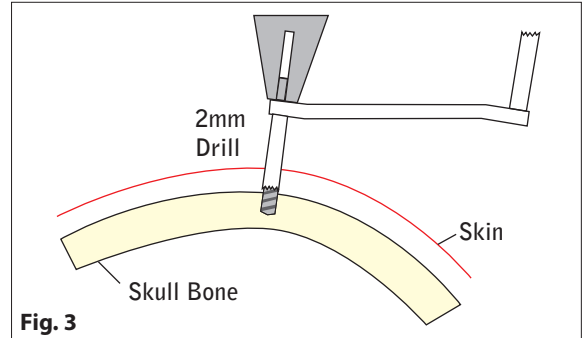


Fig. 3

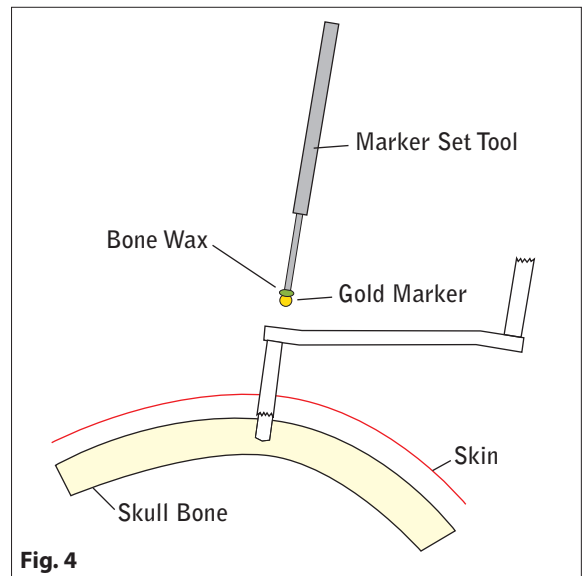


Fig. 4

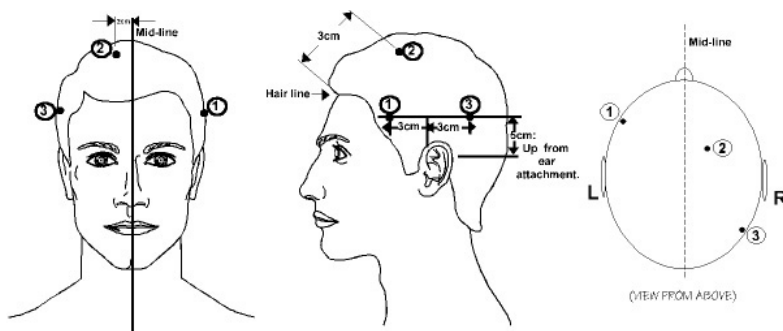


Fig. 5

Gold Marker Placement Worksheet: Cranial

Page 2 of 2

Gold Marker Sterility

Gold Markers supplied by CIVCO Medical Solutions are not sterile unless specified otherwise.

Metallic internal fixation devices must be sterilized prior to surgical use. Steam sterilization is recommended using the Association for the Advancement of Medical Instrumentation (AAMI) guideline "Good Hospital Practice: Steam Sterilization and Sterility Assurance." The AAMI website can be found at www.aami.com.

Gold Marker Physical Data

Boiling Point.....	2808° C	Evaporation Rate (butyl acetate+1).....	0
% Volatile.....	0	Vapor Density (air=1).....	N/A
Solubility in Water.....	Insoluble	Vapor Pressure.....	1mm @ 1869° C
Specific Gravity (H ₂ O = 1).....	19.3	Appearance and Odor	Yellow metallic spheres; odorless
Melting Point.....	1063° C		

Typical Operative Report

Physician Name: Dr. B

Department: Neuro

Note Type: Operative Report

The accuracy of this note has not been verified by the dictating physician.

Hospital: "A" - Seattle, Washington

Operative Record

Patient #: 123456

Patient: Mr. X

Operative Date: 12/5/2005

Preoperative Diagnosis: Left frontal metastatic adenocarcinoma.

Postoperative Diagnosis: Left frontal metastatic adenocarcinoma.

Procedure: Implantation of Gold Markers for Linac irradiation.

Surgeon: Dr. B

History and Indications: This 62-year old woman has known metastatic adenocarcinoma of lung to brain.

Procedure: Under satisfactory local anesthesia, a stab wound was made approximately 5cm off the midline in the left frontal region and homeostasis achieved. Using a 2mm drill a small hole was made through the outer table into the diploic space. A Gold Marker was then implanted and then bone waxed over. The wound was closed with interrupted #4-0 Nurolon. The procedure was exactly repeated on the right side approximately 5cm off the midline and more posterior than the left and then again in the right posterior Varietal region. Estimated blood loss was nil and the patient was discharged well from the operating room.



Technical Support: 866.851.4355 | Customer Service and Sales: 800.842.8688 | 712.737.8688

WWW.CIVCO.COM